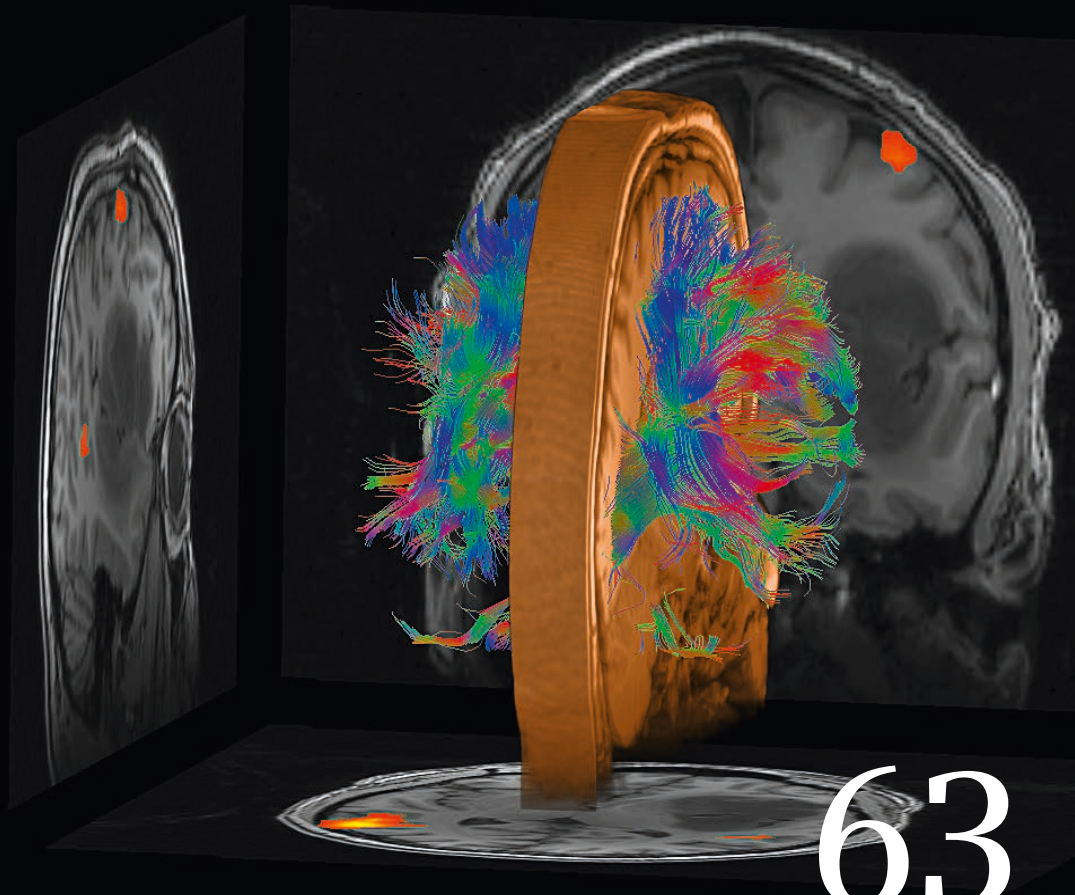
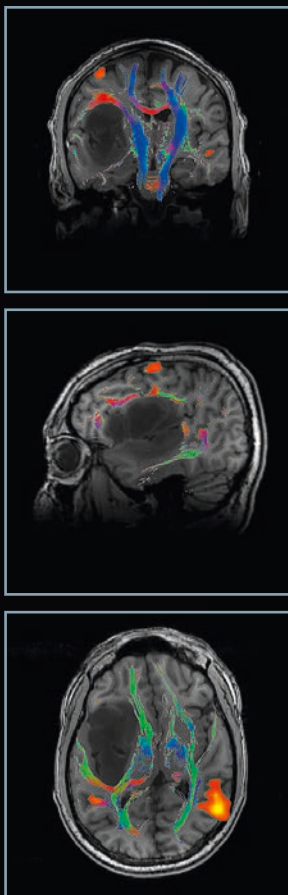


MAGNETOM Flash

The Magazine of MRI

Issue Number 3/2015 | Simultaneous Multi-Slice Supplement

Not for distribution in the US



**Editorial
Comment**
Peter Jezzard
Page 3

SMS Diffusion
*Kawin Setsompop
et al.*
Page 16

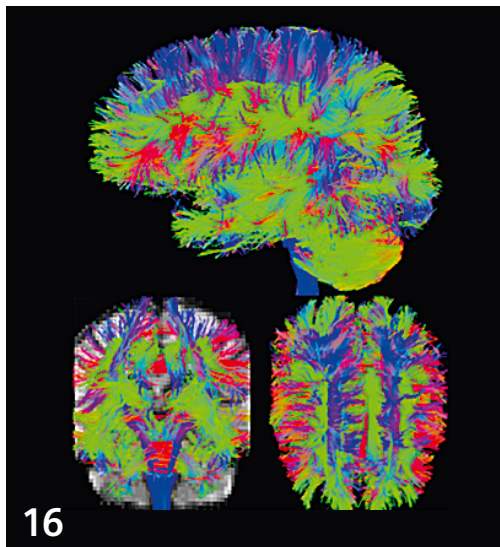
**SMS Diffusion
in clinical
Neuroradiology**
Timothy Shepherd
Page 24

SMS BOLD
*Kâmil Uğurbil
et al.*
Page 49

**Presurgical
Mapping with
SMS BOLD fMRI
and SMS Diffusion**
Andreas Bartsch
Page 58

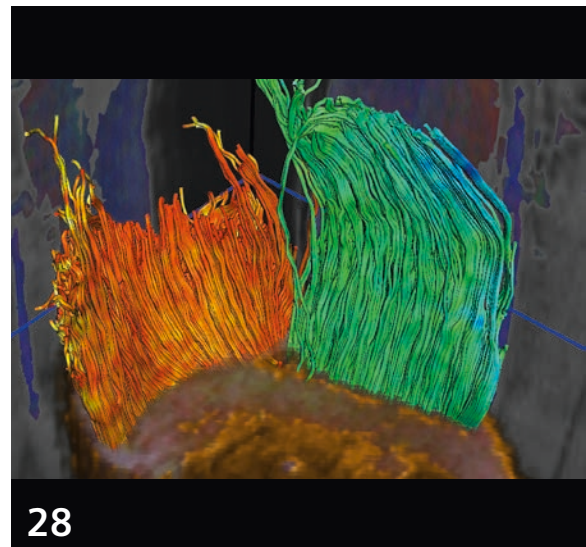
**Improving Sensitivity
and Specificity
in BOLD fMRI Using
SMS Acquisition**
Richard Hoge et al.
Page 65

Content



16

Advancing Diffusion MRI Using SMS EPI

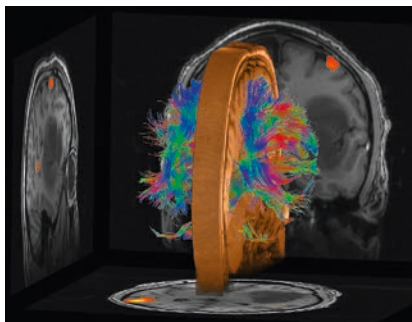


28

Accelerated DTI of Skeletal Muscle Using SMS Acquisition

Editorial Comment

- 2** The SMS Revolution
Peter Jezzard, FMRIB Centre, University of Oxford, UK



Cover image courtesy of Andreas J. Bartsch (Radiologie Bamberg, Germany; Departments of Neuroradiology, Universities of Heidelberg and Wuerzburg, Germany; Oxford Centre for Functional MRI of the Brain (FMRIB), University of Oxford, UK)

SMS Diffusion

- 08** CAIPIRINHA – Revisited
Felix Breuer, et al., Research Center, Magnetic Resonance Bavaria, Würzburg, Germany
- 16** Advancing Diffusion MRI Using SMS EPI
Kawin Setsompop, et al., Massachusetts General Hospital, Charlestown, MA, USA
- 24** High Potential Impact of SMS Diffusion Acquisition Strategies on Future Clinical Neuroradiology Practice
Timothy Shepherd, New York University, NY, USA
- 28** Accelerated DTI of Skeletal Muscle Using SMS Acquisition
Lukas Filli, et al., University Hospital Zurich, Switzerland
- 32** SMS Accelerated Free-Breathing DWI in Abdomen and Pelvis
Hersh Chandarana, et al., NYU School of Medicine, New York, NY, USA
- 36** Rapid High Spatial Resolution Diffusion MRI at 7 Tesla Using SMS Acquisition
Cornelius Eichner, et al., Max Planck Institute for Human Cognitive and Brain Sciences, Leipzig, Germany
- 39** Myocardial First-Pass Perfusion Imaging with High Resolution and Extended Coverage Using Multi-Slice CAIPIRINHA
Daniel Stäb, et al., Institute of Radiology, University of Würzburg, Germany
- 46** Cardiac Diffusion Tensor MRI Using SMS Acquisition with a Blipped-CAIPIRINHA Readout
Choukri Mekkaoui, et al., Massachusetts General Hospital, Harvard Medical School, Boston, MA, USA

The information presented in MAGNETOM Flash is for illustration only and is not intended to be relied upon by the reader for instruction as to the practice of medicine. Any health care practitioner reading this information is reminded that they must use their own learning, training and expertise in dealing with their individual patients. This material does not substitute for that duty and is not intended by Siemens Healthcare to be used for any purpose in that regard. The treating physician bears the sole responsibility for the diagnosis and treatment of patients, including drugs and doses prescribed in connection with such use. The Operating Instructions must always be strictly followed when operating the MR system. The source for the technical data is the corresponding data sheets.