

FSL Course 2016**Clinical (Presurgical) Applications
of FMRI & Tractography using FSL**

Andreas J. Bartsch

Dep. of Neuroradiology, University of Heidelberg
 Dep. of Neuroradiology, University of Wuerzburg
 FMRI Centre, University of Oxford
 Radiology Bamberg, Germany

bartsch@radvisory.net

Outline of the Talk

- Clinical Challenge → Clinical Relevance → Solution *(Is there any?, How can FSL help?)*
- Focus on Language Networks, Auditory System & Pyramidal Tract: FMRI-Mapping & DW-Tractography *(with Xing fibres modeling)*
- Case-based Illustrations
 - FMRI / Tractography prior to 'bionic' (cochlear) implantation*
 - Assessing Interhemispheric Dominance ("Lateralisation") prior to Epilepsy Surgery*
 - Presurgical Planning / Intraoperative Neuro-navigation for Resection of Intraaxial Lesions*

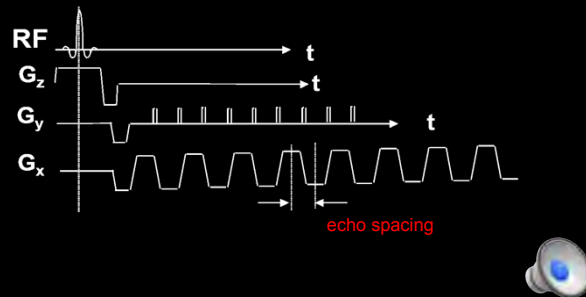
Outline of the Talk

- Clinical Challenge → Clinical Relevance → Solution *(Is there any?, How can FSL help?)*
- Focus on Language Networks, Auditory System & Pyramidal Tract: FMRI-Mapping & DW-Tractography *(with Xing fibre modeling)*
- Case-based Illustrations
 - FMRI / Tractography prior to 'bionic' (cochlear) implantation*
 - Assessing Interhemispheric Dominance ("Lateralisation") prior to Epilepsy Surgery*
 - Presurgical Planning / Intraoperative Neuro-navigation for Resection of Intraaxial Lesions*

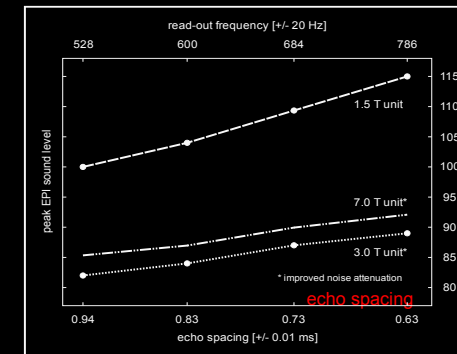
Outline of the Talk

- Challenge → Clinical Relevance → Solution *(Is there any?, How can FSL help?)*
- Focus on Language Networks, Auditory System & Pyramidal Tract: FMRI-Mapping & DW-Tractography *(with Xing fibre modeling)*
- Case-based Illustrations
 - FMRI / Tractography prior to 'bionic' (cochlear) implantation*
 - Assessing Interhemispheric Dominance ("Lateralisation") prior to Epilepsy Surgery*
 - Presurgical Planning / Intraoperative Neuro-navigation for Resection of Intraaxial Lesions*

Challenge: Echo-Planar Imaging (EPI) is LOUD

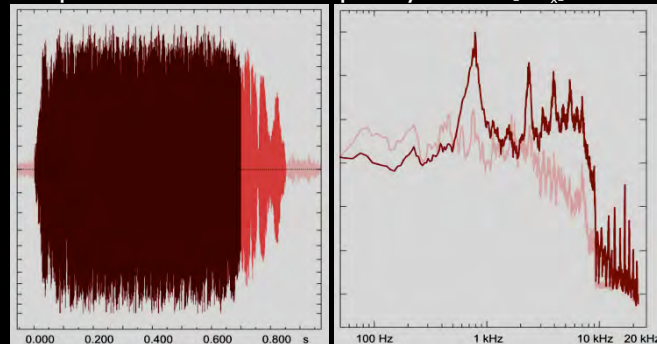


Challenge: Echo-Planar Imaging (EPI) is LOUD



Fundamental Frequency Peak of EPI

- depends on read-out frequency of EPI [$\pm G_x$]

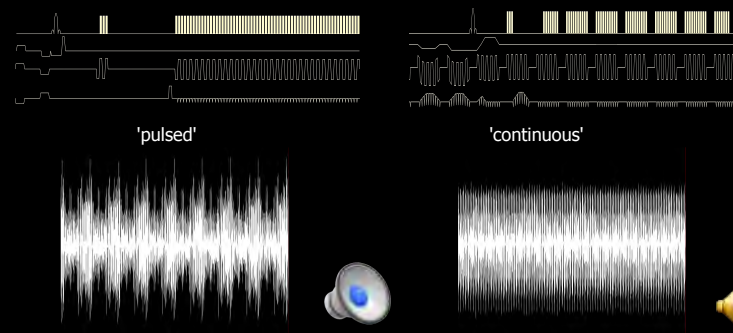


Bartsch et al., *NeuroImage* 2007

EPI is LOUD: Clinical Consequence

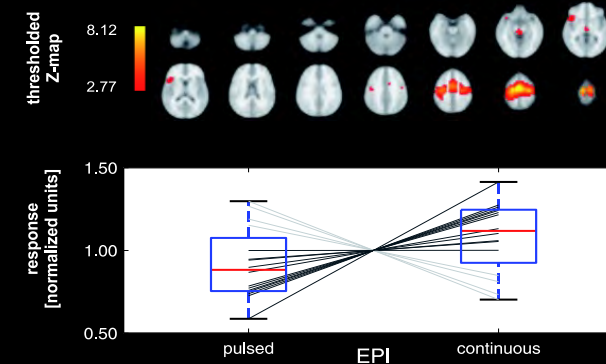
- Reduced patient comfort
- Startle movements
- Impaired audio transmission
- Reduced fMRI-activations

Solution 1: Low Impact Noise Acquisition or 'Continuous' EPI



Seifritz et al., *NeuroImage* 2006 (courtesy of K. Scheffler)

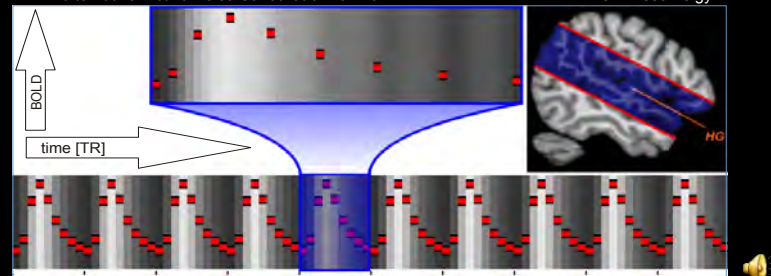
... can increase FMRI-Responses



Haller et al., *Brain Res* 2009

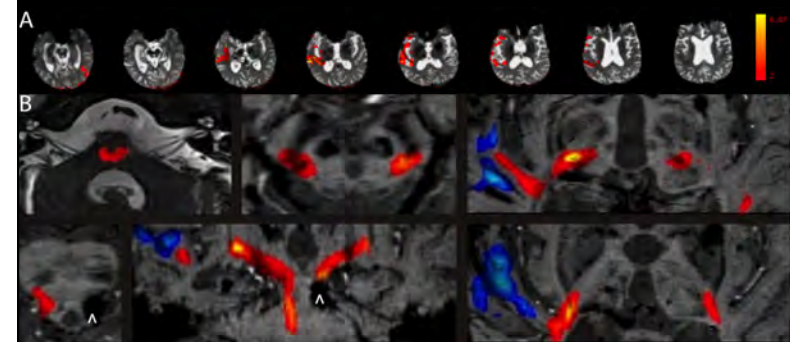
Can Acoustic EPI Noise be useful? FMRT-Audiometry by Read-Out Omissions

- EPI Read-Out [■] evokes auditory activations*
 - omissions of [■] yield detectable BOLD-fluctuations#
- alternative: Active Noise Cancellation* on / off HG = Heschl's gyri

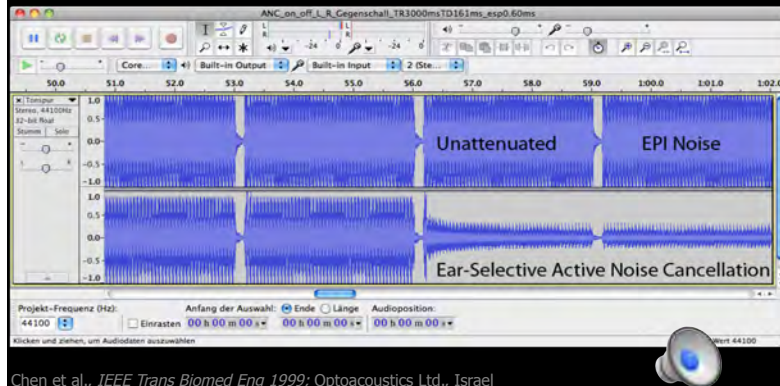


Bartsch et al., **Riv Neuroradiol* 2003/**NeuroImage* 2007; °Chen et al., *IEEE Trans Biomed Eng* 1999

FMRT-Audiometry, -Promontory Testing & Tractography of the Auditory Radiation prior to CI in TBI (diffuse axonal shearing injury)



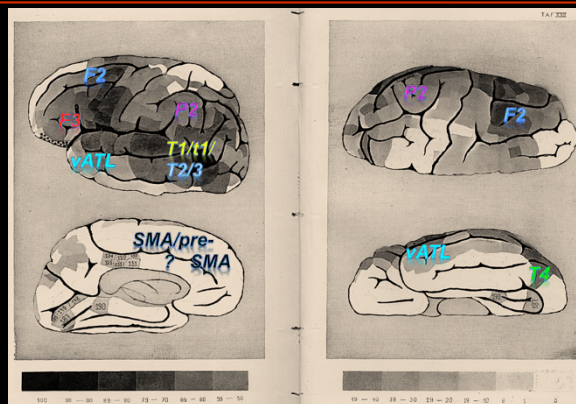
Solution 2 (to reduce EPI Noise): Active Noise Cancellation (ANC)



Challenge *Before* You Start Mapping

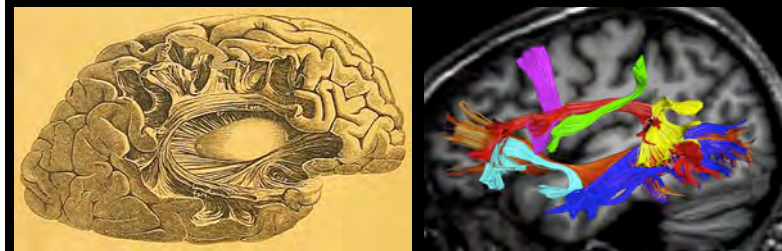- **detect** the lesion (*if there is any*)
& establish its location with respect to the presumed components of the functional network(s) of interest (FNOI; e.g. speech / language)
- **detect** even subtle deficits of the patient
- **select** the best paradigm

"Relative" Language Areas



Dax, 1836 (?); Broca, 1861; Meynert, 1866; Wernicke, 1874; Exner, 1881; Mills & Martin, 1912

Ventral & Dorsal Fibre Pathways implied in Speech & Language



Meynert, 1884; Catani & Budisavljevic, 2014;
cf. Rolheiser et al., *J Neurosci* 2011; Duffau et al., *J Neurosurg* 2008

Challenge *Before* You Start Mapping

- **detect** the lesion (*if there is any*)
& establish its location with respect to the presumed components of the functional network(s) of interest (FNOI; e.g. speech / language)
- **detect** even subtle deficits of the patient
- **select** the best paradigm

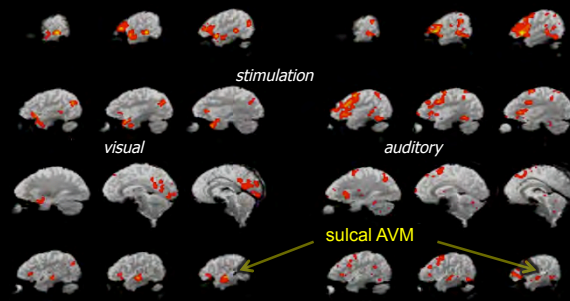
Challenge *Before* You Start Mapping

- **detect** the lesion (*if there is any*)
& establish its location with respect to the presumed components of the functional network(s) of interest (FNOI; e.g. speech / language)
- **detect** even subtle deficits of the patient
- **select** the best paradigm

FMRI-Activations are variable and should be evoked optimally

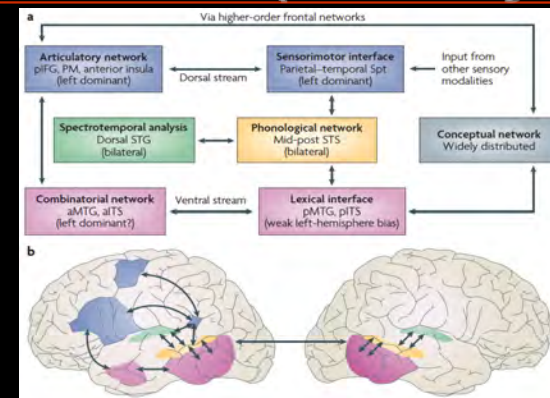
speech mapping: same patient, **different paradigms**

Reading nonfinal embedded clause sentences vs. Auditory description-cued covert naming



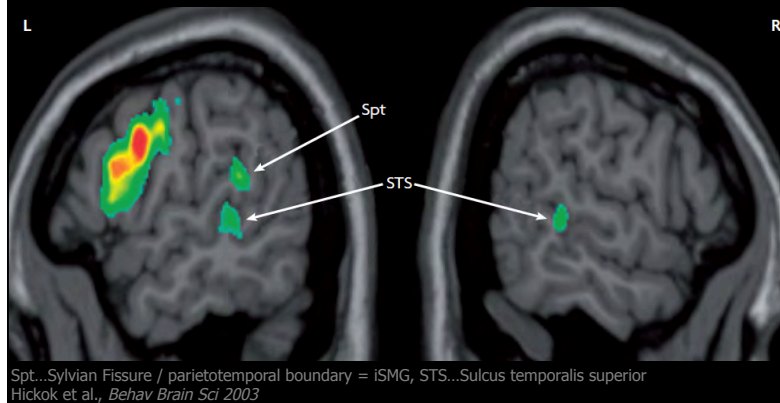
Bartsch et al., *JMRI* 2006

Just "Messy Maps" ? Dual Stream for Speech & Language !



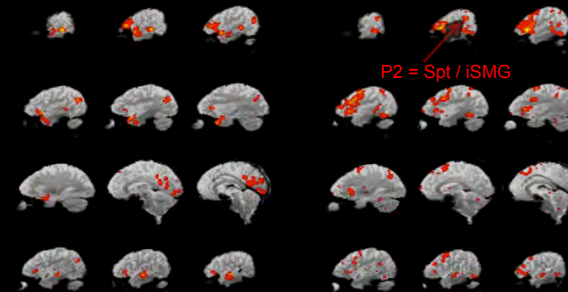
Hickok & Poeppel, *Nat Neurosci* 2007; Ueno et al., *Neuron* 2011

Lateralisation in Auditory-Motor (Phonological) Activations

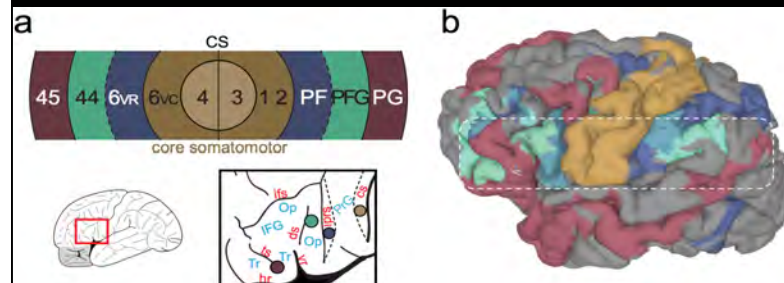


"Messy Maps" – Revisited: Different Components of the FNOI

speech mapping: same patient, **different paradigms**
Reading nonfinal embedded clause sentences vs. Auditory description-cued covert naming

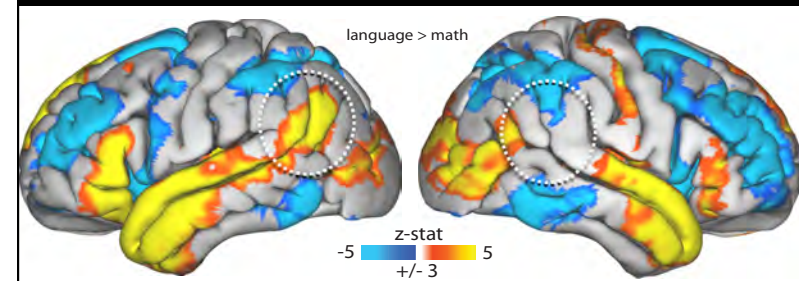


Speech/Language-Lateralisation & Mirror Connectivity around the CS

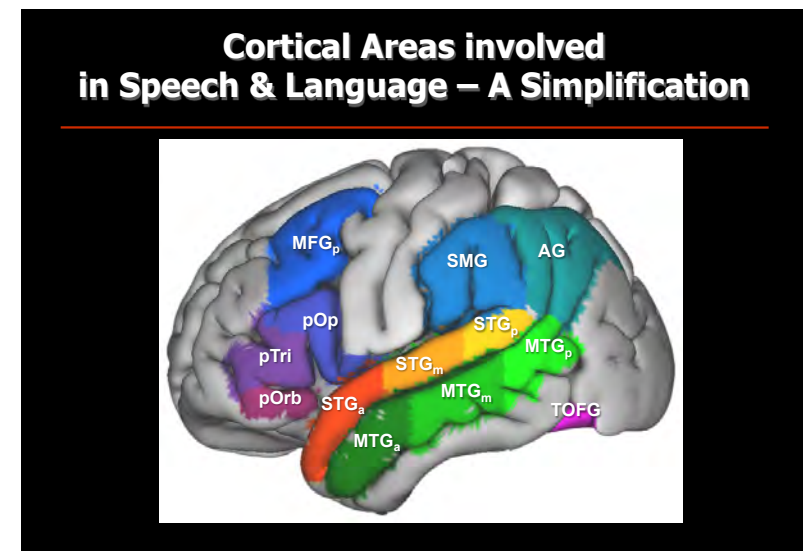
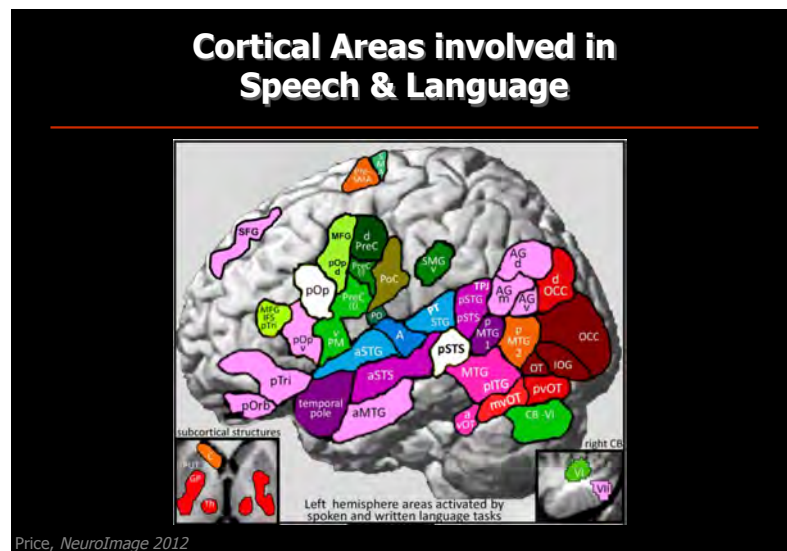
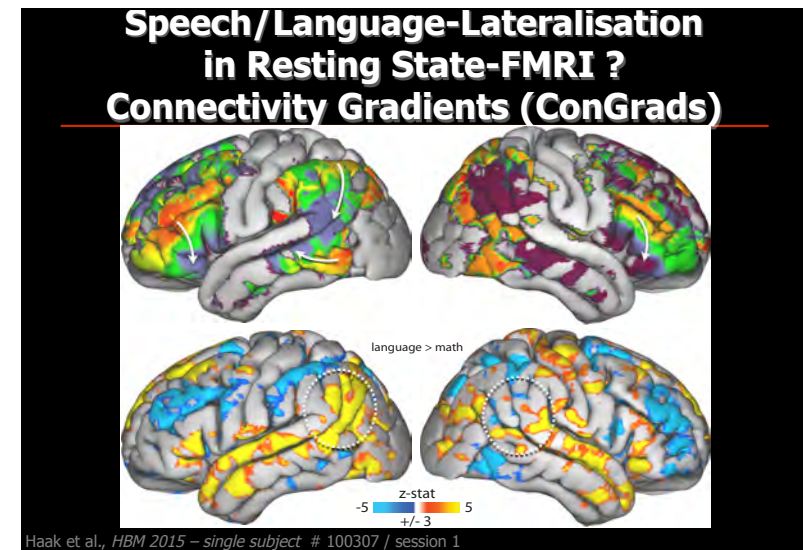


Margulies & Petrides, *J Neurosci* 2013 – n=6 subjects

Speech/Language-Lateralisation in Resting State-FMRI ? Task-FMRI Reference Results



Haak et al., *HBM* 2015 – n=60 HCP subjects, 8 min



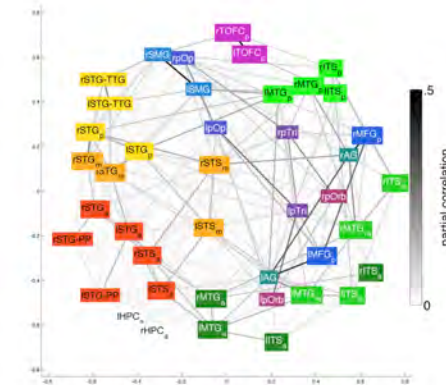
Why Graph Theory ?

Wir weisen also die Annahmen zurück, daß der Sprachapparat aus gesonderten Zentren bestehe... Die "Zentren" [erscheinen] als die Ecken des Sprachfelds...

Freud, 1891

BOTH HEMISPHERES

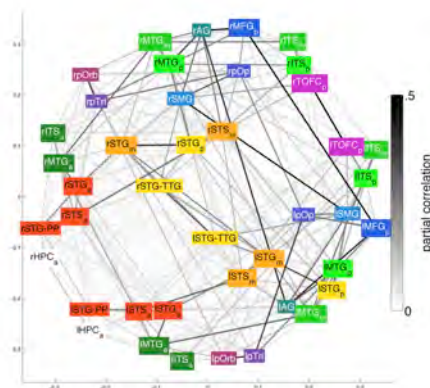
Dual stream model for speech processing Hickok and Poeppel (2007)



Results from Multidimensional Scaling (MDS) of Resting State-FMRI Data
(n=470 HCP subjects; courtesy of Izabela Przezdziak & Koen Haak)

BOTH HEMISPHERES

Dual stream model for speech processing Hickok and Poeppel (2007)

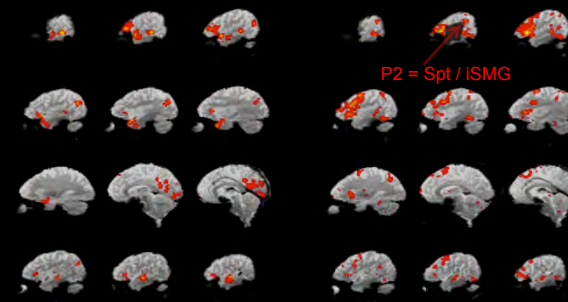


Results from Multidimensional Scaling (MDS) of Task-FMRI Data
(n=470 HCP subjects; courtesy of Izabela Przezdziak & Koen Haak)

FMRI-Activations are variable and should be evoked optimally

speech mapping: same patient, **different paradigms**

Reading nonfinal embedded clause sentences vs. Auditory description-cued covert naming

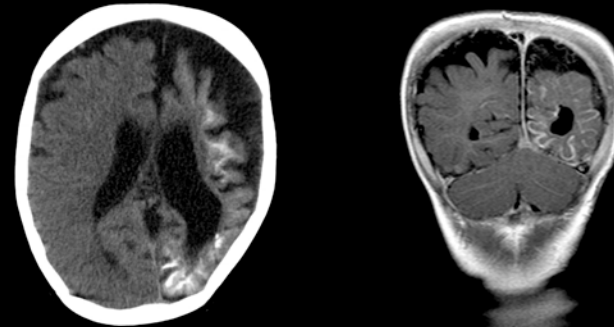


Solution

Based upon detailed neuropsychological examination:

- Visual vs. auditory stimulation
- Performance-adjusted presentation speed
- Task-based vs. -free (*=passive*) paradigm
- Event-related vs. blocked design

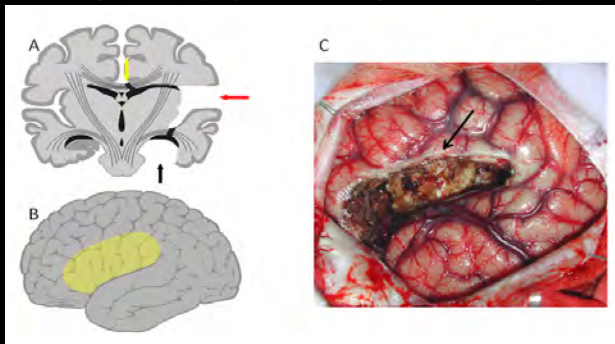
AUDIENCE CASE 1: 9-yo Boy, Refractory (Lesional) Epilepsy



right hemiparesis & -anopsia, glaucoma,
speech slow & slurred but preserved during seizures (3rd grade, inclusion)

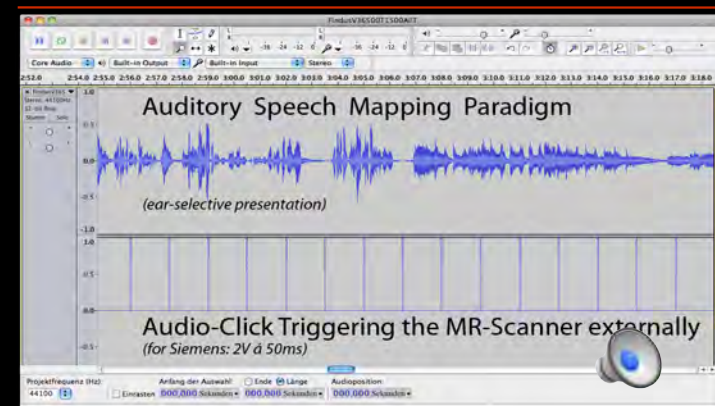
What is the Diagnosis, why is an FMRI requested ?

encephalotrigeminal angiomatosis (Sturge-Weber syndrome);
establish speech / language lateralization prior to left hemispherotomy*

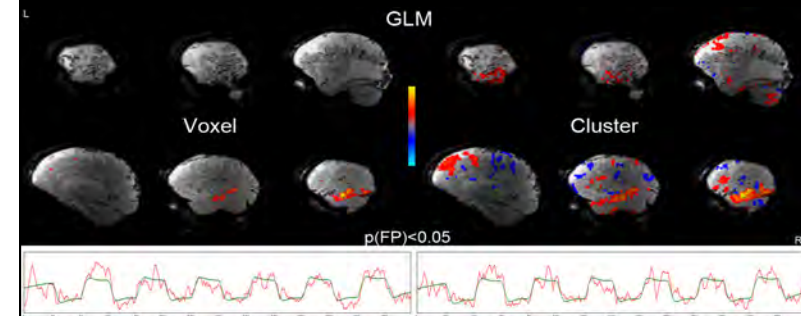


*Terra et al., 2011

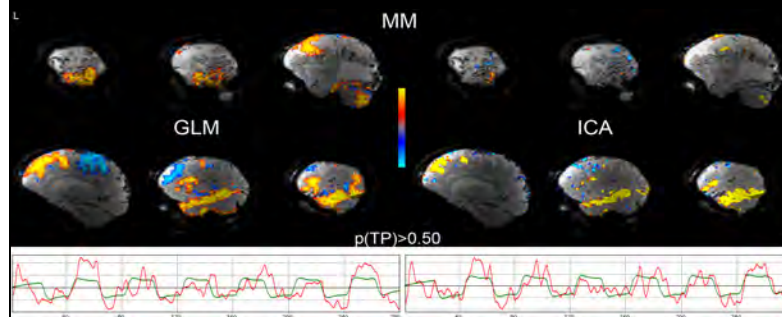
How do we map this patient BEST ?



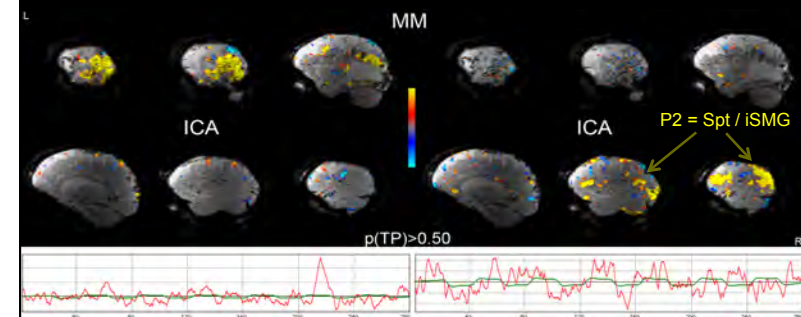
Audio-Trigger: Bartsch, DGNR 2012; Homola et al., PLoS One 2012

CHALLENGE:**How do we analyze the data ?****What do we test for ?****CLINICAL RELEVANCE:****What we are going to find will vary !****Hypothesis-driven Analysis,
Family-wise Error Rates (FWER) <5%**

cf. Worsley, 2001 (In: Functional MRI, Eds.: Jezzard, Matthews & Smith)

**Hypothesis- vs. Data-driven Analysis,
(De-)Activation Probabilities >50%**

Mixture Modeling (MM) & H(1)-Testing: Beckmann et al., *HBM Conf. 2003*; Beckmann & Smith, *IEEE TMI 2004*; Everitt & Bullmore, *HBM 1999*; Hartvig & Jensen, *HBM 2000*; Woolrich et al., *IEEE TMI 2005*; Durnez et al., *CABN 2013*; Johnson et al., *Stat Methods Meds Res 2013*

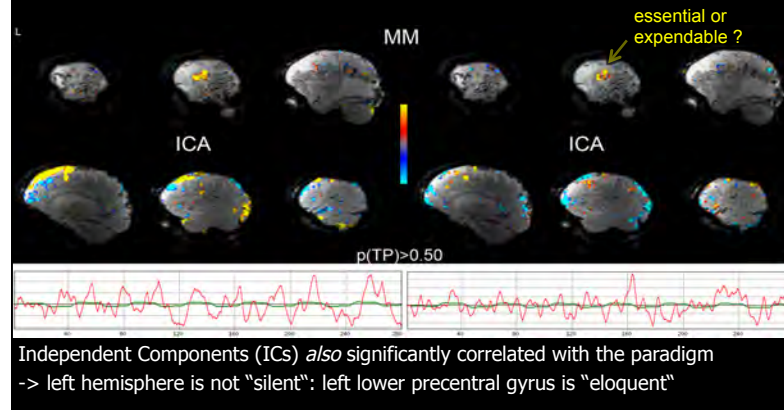
**Data-driven Analysis (ICA),
(De-)Activation Probabilities >50%**

Independent Components (ICs) also significantly correlated with the paradigm

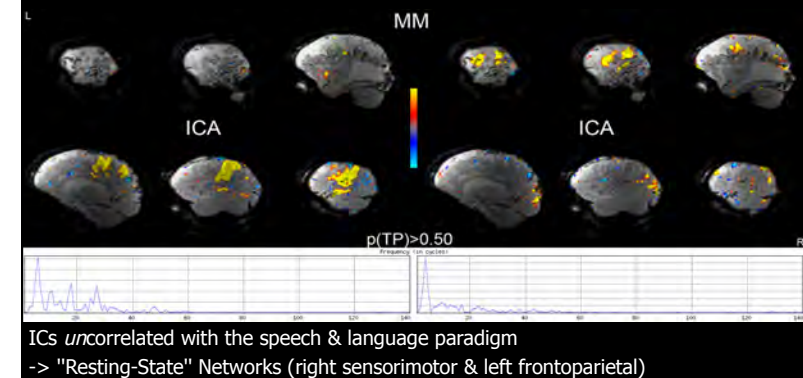
-> Is left hemisphere "silent"? - speech dissociates in pSTG/vAPL-ICs*

*cf. Simmonds et al., *HBM 2013*

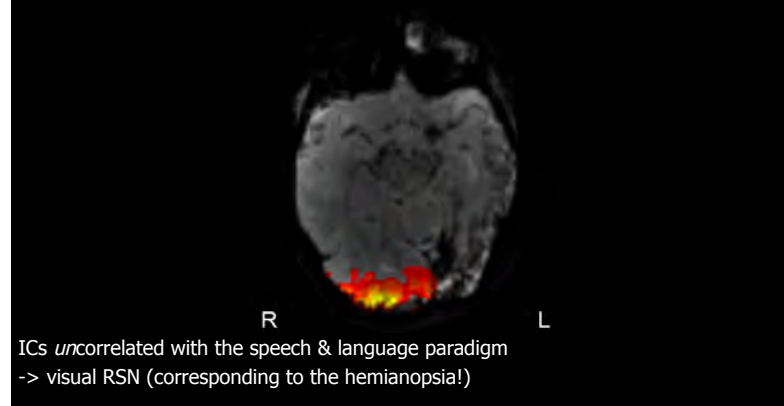Solution: Use GLM & ICA, Alternative Hypothesis Testing



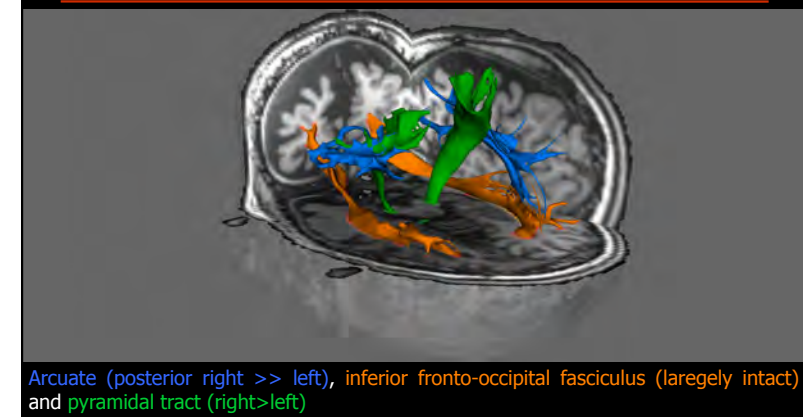Data-driven Analysis (ICA), (De-)Activation Probabilities >50%



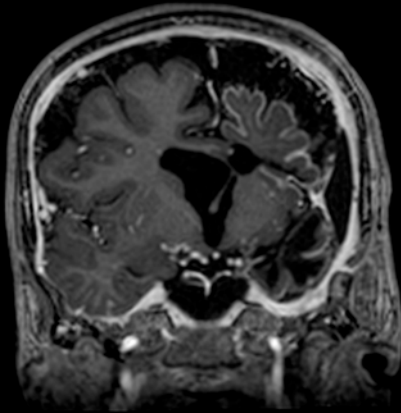
Data-driven Analysis (ICA), (De-)Activation Probabilities >50%



and Diffusion Tractography ?



Hemispherectomy and Outcome



CHALLENGE:

Which Blobs / Tracts are (in-)dispensable ?
How far do they extend ?

CLINICAL RELEVANCE:

Huge – our clinical decisions will vary !

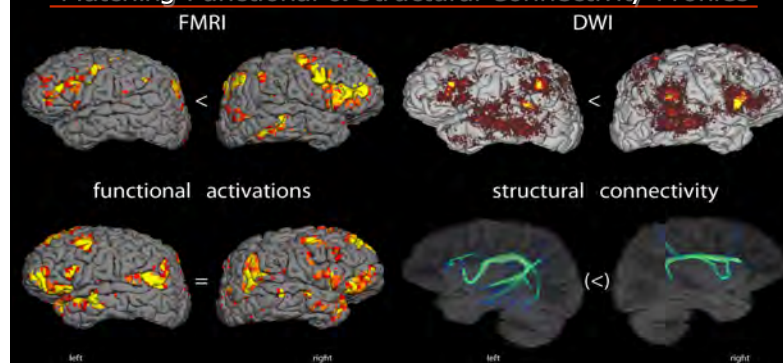
SOLUTION:

NONE (yet) 😞

but maybe there is hope...

COMPANION CASE 2: 13-yo Boy, Refractory *Nonlesional* Epilepsy

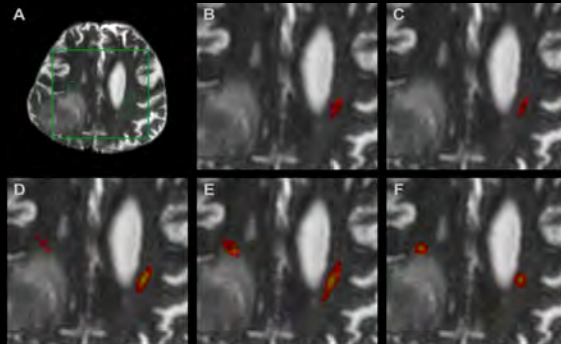
Matching Functional & Structural Connectivity Profiles



Left-Hander, hypermotor left frontotemporal seizures with aggressive behaviour & preserved speech
Question: speech / language lateralization prior to invasive electrocorticography

Challenge: Tracking in Perifocal Edema increases False-Negatives

right retro-Rolandic glioblastoma (A), simple (B) vs. interpolated (B) streamlining, probabilistic tractography without (D) & with (E) Xing fibres + constrained Bayesian (F)

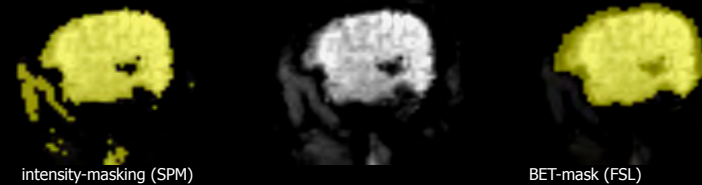


Bartsch et al., 2014 (In: Diffusion MRI, Eds.: Johansen-Berg & Behrens)

CHALLENGE: EPI suffers from LOCAL SIGNAL LOSS

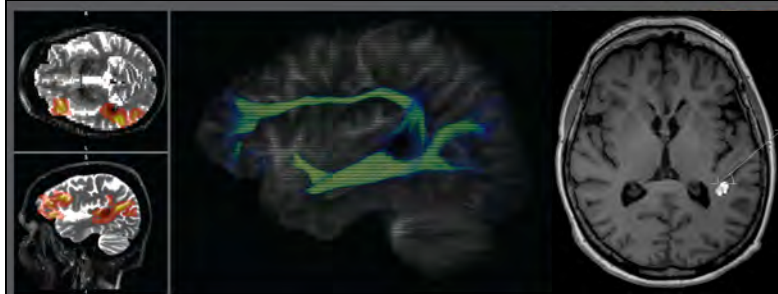
- bleedings, flow-void, drilling abrasions, calcinations etc. altering the EPI signal

→ *Make sure lesion is covered by analysis mask! Always look at original EPI (not just stats-overlays on highres anatomical)!*
arteriovenous malformation (AVM; hypointense flow-void)



Haller & Bartsch, Eur Radiology 2009

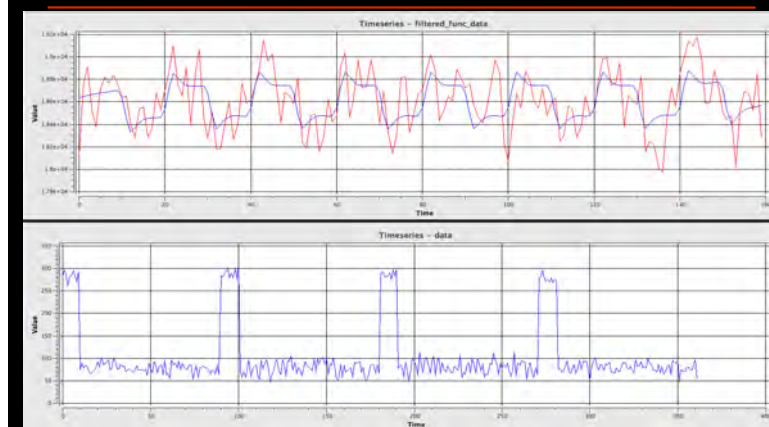
CLINICAL RELEVANCE: No Signal – No Activations / Tracts



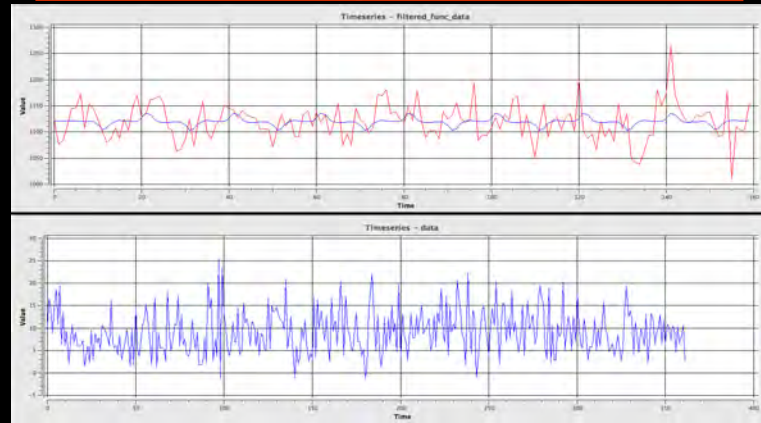
left temporal cavernoma (Zabramski type I; intracellular MetHb)

Bartsch et al., 2014 (In: Diffusion MRI, Eds.: Johansen-Berg & Behrens)

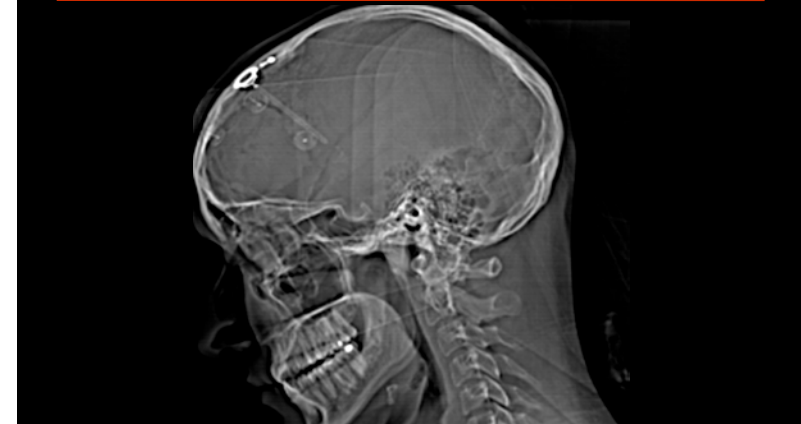FMRI- & Diffusion-EPI SIGNAL



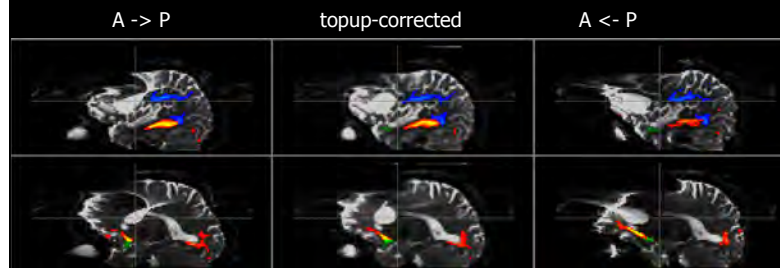
FMRI- & Diffusion-EPI **SIGNAL LOSS:** No easy solution !



CHALLENGE: DISTORTIONS



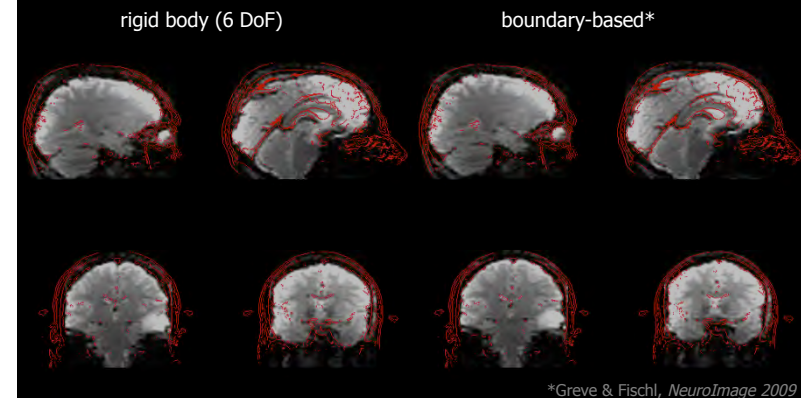
CHALLENGE: EPI suffers from GEOMETRIC DISTORTIONS...



Arcuate, inferior fronto-occipital and uncinate fasciculus
in a ganglioglioma patient with craniofix & a Ommaya reservoir

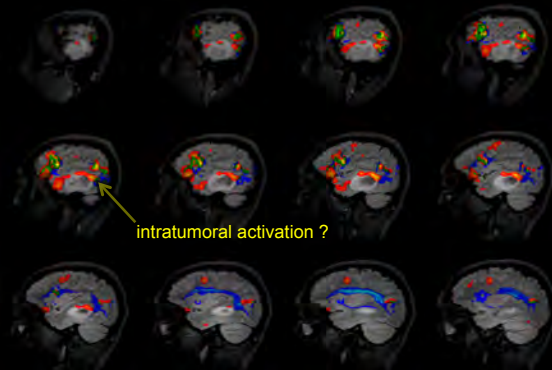
Anderson, 2014 (In: Diffusion MRI, Eds.: Johansen-Berg & Behrens); Choli et al., MAGMA 2013

...and, for GE-EPI, SIGNAL DROPOUTS can cause REGISTRATION ERRORS



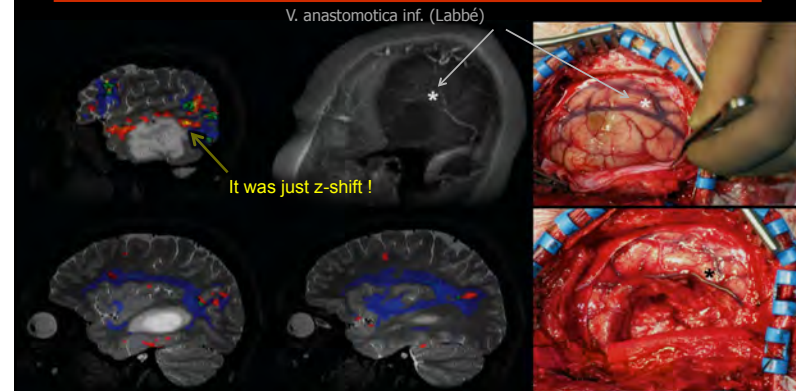*Greve & Fischl, NeuroImage 2009

CLINICAL RELEVANCE - CASE 3: Incidental left T2/3-Astrozytoma °III



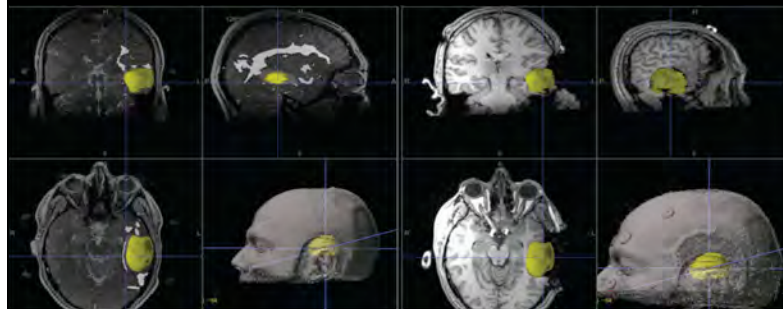EPI signal dropout can cause a Z-shift of the EPI -> structural registration

SOLUTION: Optimal Distortion Correction & Registration for Presurgical Planning

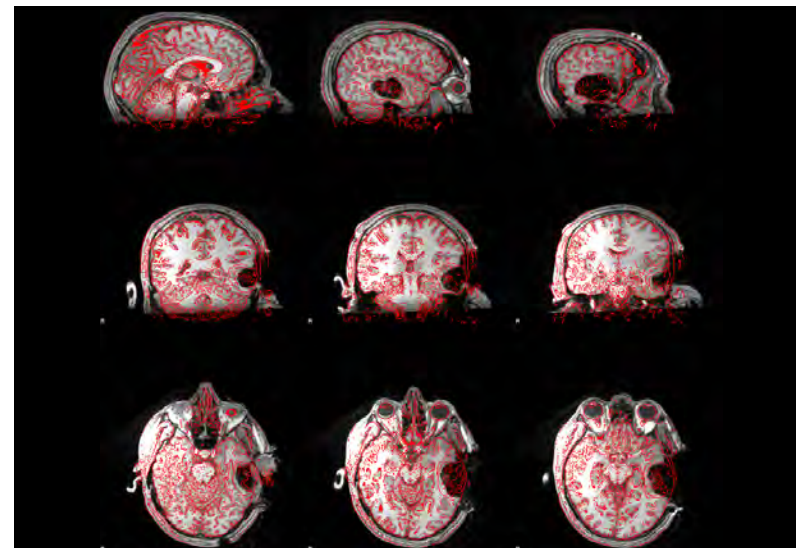


paradigm: reading non-final embedded clause sentences

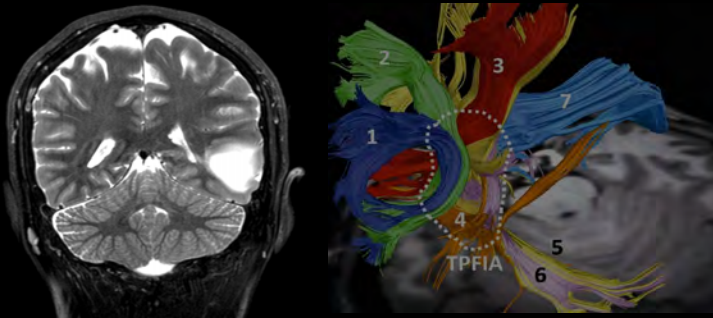
and Intraoperative Neuronavigation !



... but what about brain shift ?
Here is none!

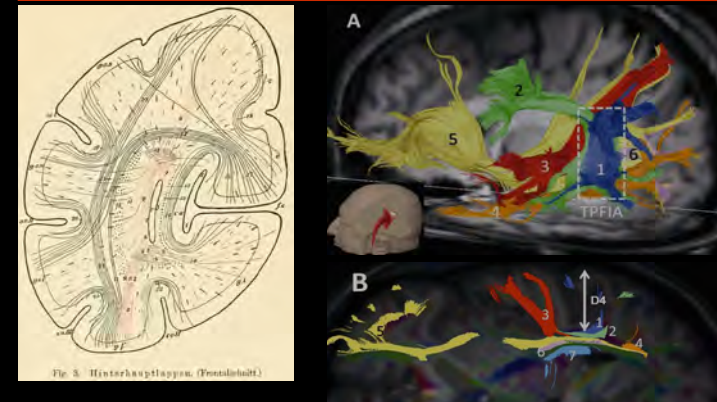


Gross Tumor Resection (GTR) – Is the Deficit predictable ?



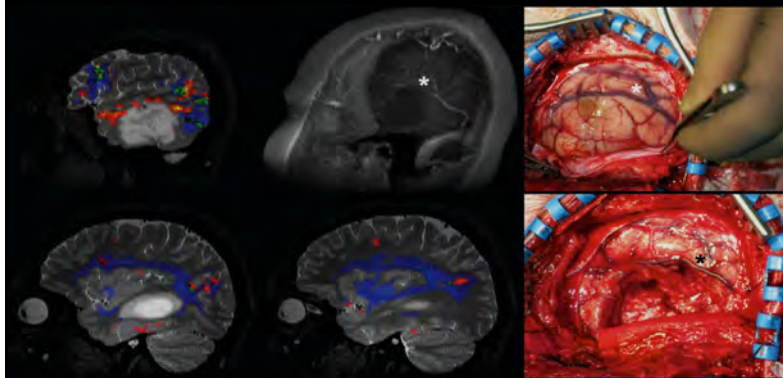
Martino et al., *Neurosurgery* 2012

"Temporoparietal Fiber Intersection Area"



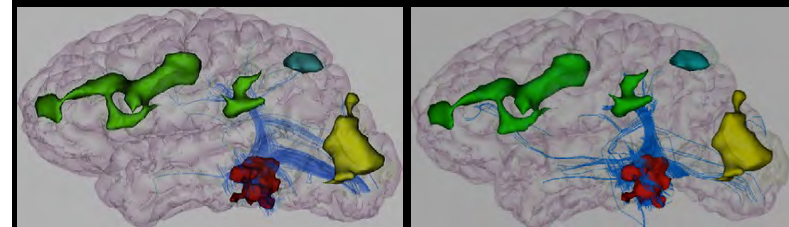
cf. Sachs, 1892; Martino et al., *Neurosurgery* 2012; Bartsch et al., *Neurosurgery* 2013

Which Deficit Would You Expect ?



"No Ifs, Ands, or Buts!"

Transient Pure Alexia without Agraphia or Hemianopsia

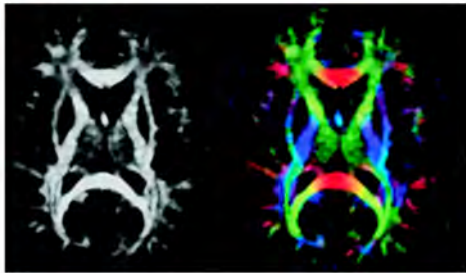


Epelbaum et al., *Cortex* 2008
Kussmaul, 1877; Charcot, 1890; Dejerine, 1892; Greenblatt, 1976-90

cf.

FMRI and Tractography: Clinically Valuable or Useless ?

NOVEMBER 2014
INTRODUCTION



Presurgical Mapping with fMRI and DTI: Soon the
Standard of Care?

AJNR, 2014

Smoothing > 7x of the Voxel Size can result in False-Negatives

ARTICLES

Three-tesla functional MR language mapping Comparison with direct cortical stimulation in gliomas

Grgory Kuchinskii, MSc,
Charles Melin, MD, PhD
Edmond Desantis, MD
Guillaume Tassi, MD
Odile Rigaux-Vodde, SLT
Pauline Roca, PhD
Xavier Leclerc, MD, PhD
Pascale Vayle, MD, PhD
Fabrice Chetani, MD,
PhD
Bernard Devaux, MD
Jean-François Mader,
MD, PhD
Catherine Oppenheim,
MD, PhD

ABSTRACT

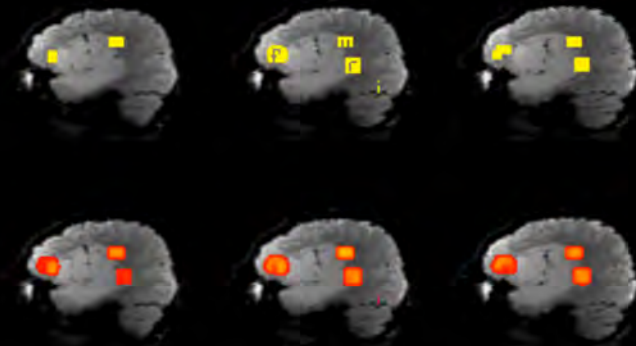
Objective: To evaluate the accuracy of functional MRI (fMRI) at 3T, as currently used in the preoperative mapping of language areas, compared with direct cortical stimulation (DCS) during awake surgery, in patients with supratentorial gliomas, and to identify clinical, histopathologic, and radiologic factors associated with fMRI/DCS discrepancies.

Methods: Language mapping with fMRI and DCS of 40 consecutive patients with gliomas (24 low-grade, 16 high-grade) in functional areas were retrospectively analyzed. Three block-designed tasks were performed during fMRI (letter word generation, category word generation, semantic association). During awake surgery, eloquent areas were mapped using DCS, blinded to fMRI. A site-by-site comparison of the 2 techniques was performed using a cortical grid. fMRI sensitivity and specificity were calculated using DCS as the reference. Associations of clinical, histopathologic, and radiologic features (including relative cerebral blood volume [rCBV]) measured with dynamic susceptibility contrast MRI with fMRI false-positive and false-negative occurrence were assessed using hierarchical logistic regressions.

Results: Of 2,114 stimulated cortical sites, 103 were positive for language during DCS. Sensitivity and specificity of language fMRI combining the 3 tasks reached 37.1% (95% confidence interval [CI] 20.7–57.2) and 83.4% (95% CI 77.1–88.3), respectively. Astrocytoma subtype (odds ratio [OR] 2.92 [1.32–6.76], $p = 0.007$), tumor rCBV (<1.5 for 2.17 [1.08–4.39], $p = 0.03$), higher cortical rCBV (OR 2.22 [1.19–4.17], $p = 0.02$), and distance to tumor >1 cm (OR 2.46 [1.82–3.32], $p \leq 0.001$) were independently associated with fMRI false-positive occurrence.

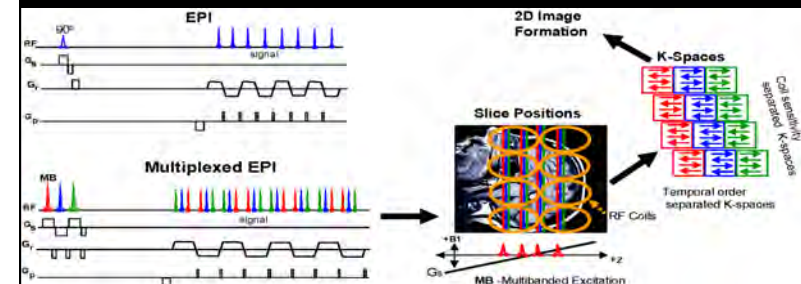
Conclusions: There are pitfalls in preoperative fMRI as currently used in preoperative language mapping in glioma patients, made more complicated when high-grade and hyperperfused tumors are evaluated. *Neurology*® 2015;84:1–9

Why / When is Spatial Smoothing “bad” ?

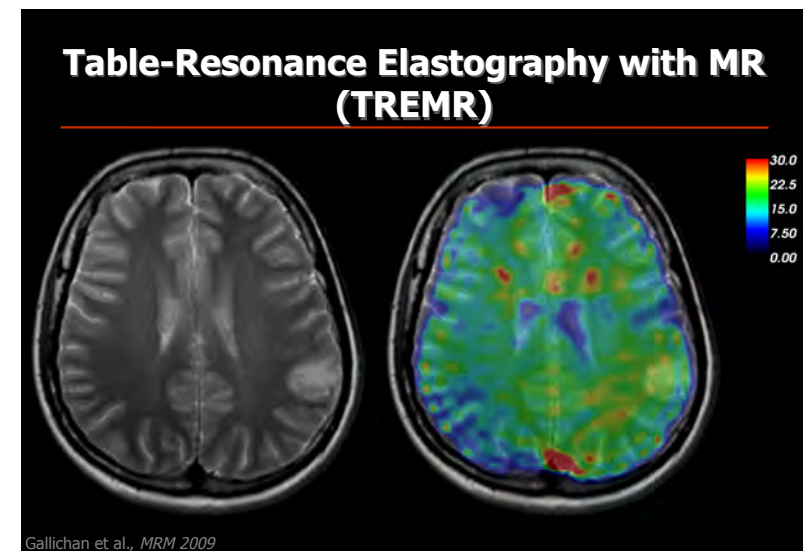
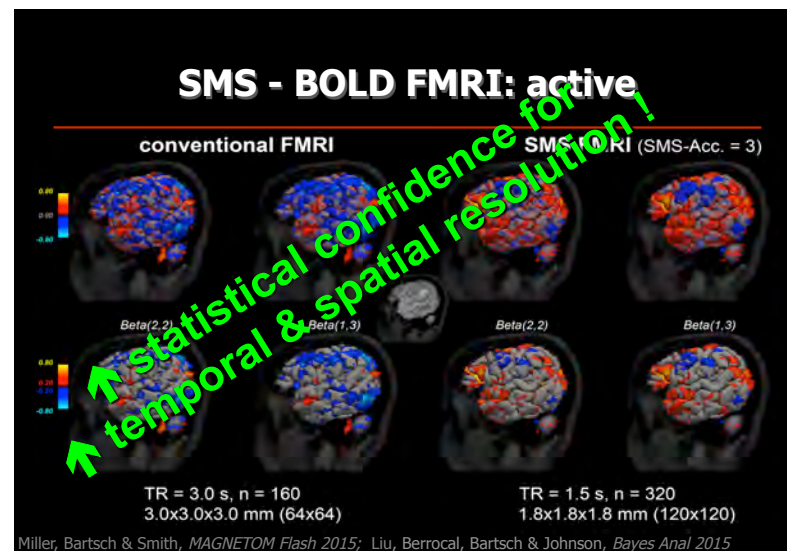
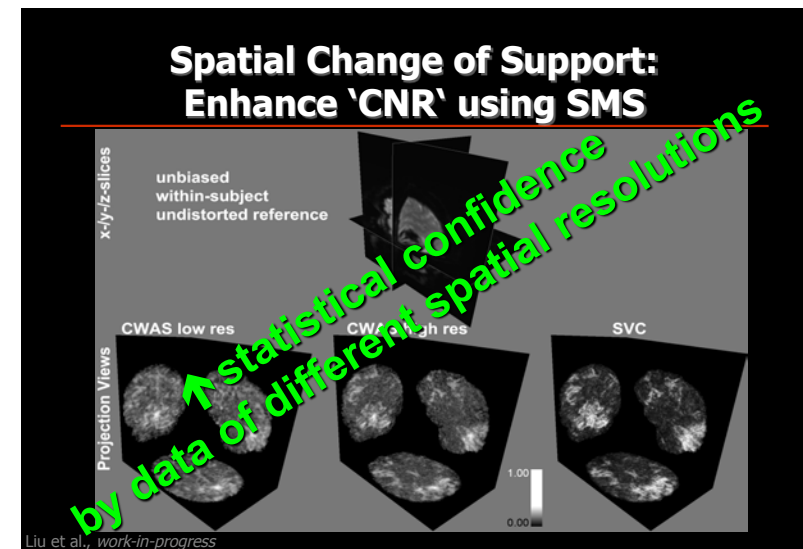
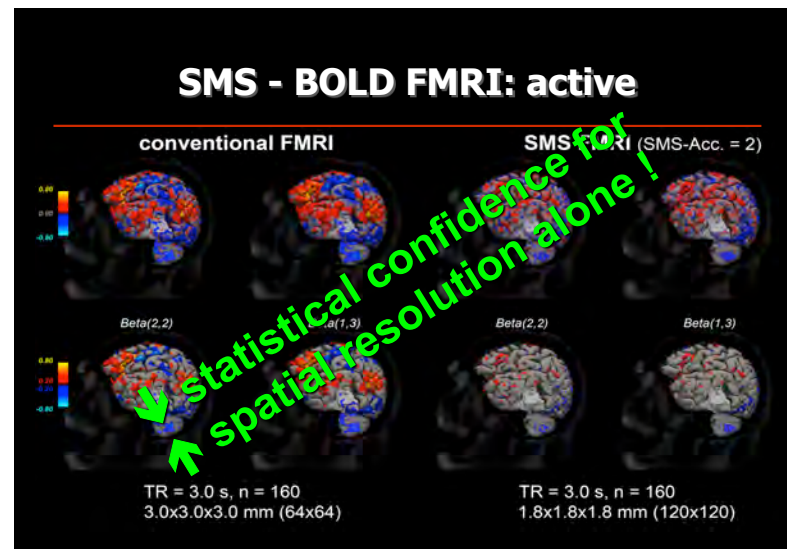


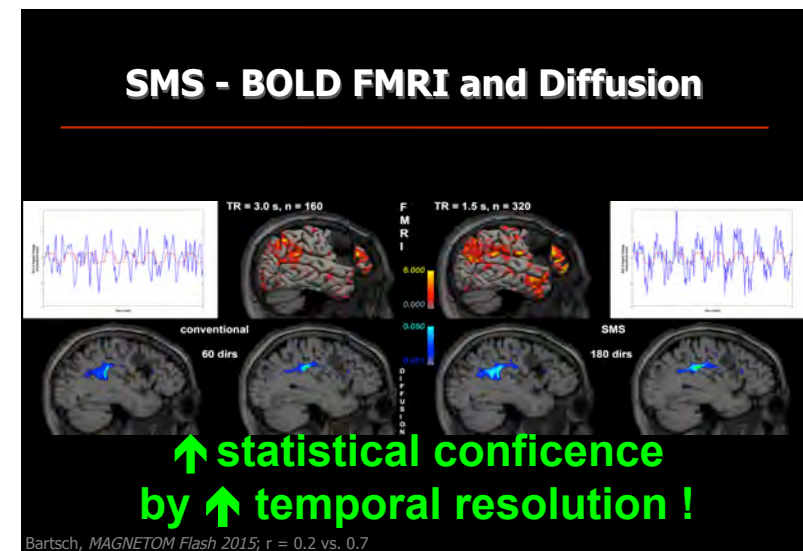
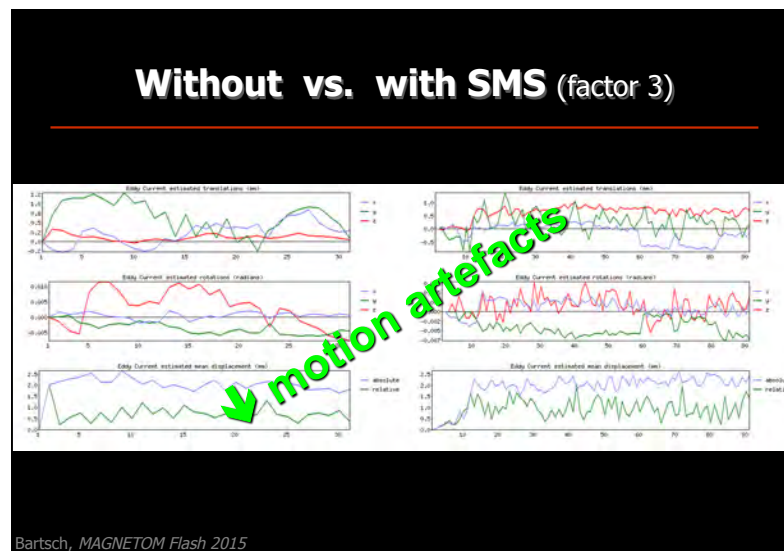
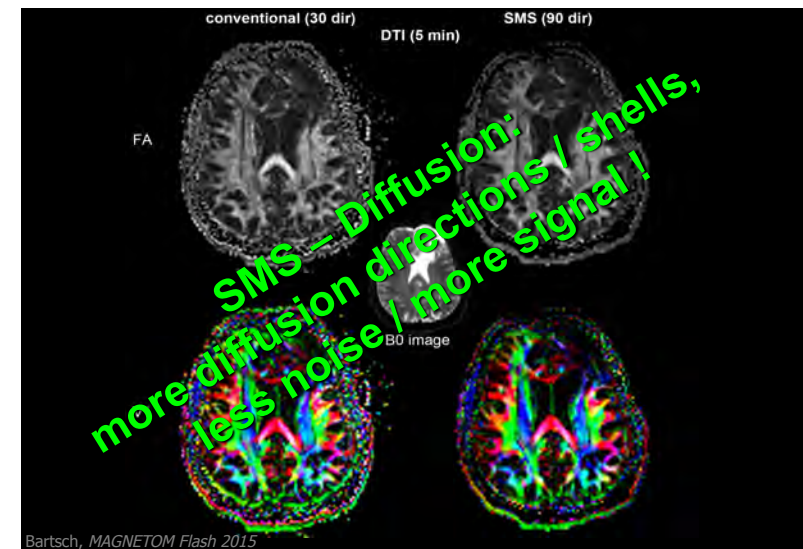
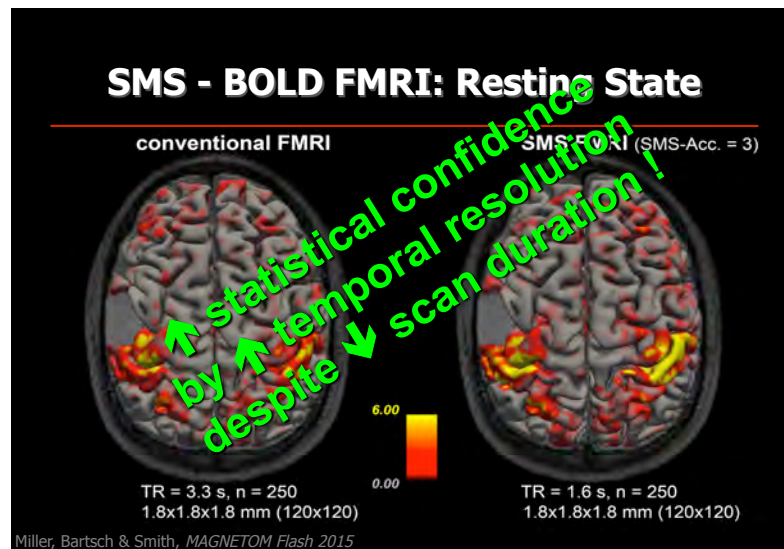
4.5 mm FWHM, spatial resolution: 1.8x1.8x2.1mm

Increase the Spatiotemporal EPI Resolution ? Simultaneous Multi-Slice !



Feinberg et al., *PLoS One* 2010





Take Home

- Preoperative patient condition matters:

epilepsy surgery - patients with no presurgical deficits or brain pathology are at high risk

tumor surgery - patients with no presurgical deficits and the small pathologies tend to fare best

- There is no uniform mapping / tracking procedure:

paradigms, seeds / targets etc. need to be tailored to the individual patient performance, deficits & pathology

- Current limitations and future challenges:

FMRI & tractography i) measure only epiphenomena of neuronal activity & axonal integrity -> false-negative risk, ii) can't discriminate essential from dispensable activations / tracts, iii) spatial extent is probabilistic

Take Home

- Preoperative patient condition matters:

epilepsy surgery - patients with no presurgical deficits or brain pathology are at high risk

tumor surgery - patients with no presurgical deficits and the small pathologies tend to fare best

- There is no uniform mapping / tracking procedure:

paradigms, seeds / targets etc. need to be tailored to the individual patient performance, deficits & pathology

- Current limitations and future challenges:

FMRI & tractography i) measure only epiphenomena of neuronal activity & axonal integrity -> false-negative risk, ii) can't discriminate essential from dispensable activations / tracts, iii) spatial extent is probabilistic

Take Home

- Preoperative patient condition matters:

epilepsy surgery - patients with no presurgical deficits or brain pathology are at high risk

tumor surgery - patients with no presurgical deficits and the small pathologies tend to fare best

- There is no uniform mapping / tracking procedure:

paradigms, seeds / targets etc. need to be tailored to the individual patient performance, deficits & pathology

- Current limitations and future challenges:

FMRI & tractography i) measure only epiphenomena of neuronal activity & axonal integrity -> false-negative risk, ii) can't discriminate essential from dispensable activations / tracts, iii) spatial extent is probabilistic

Thank You !

